

# MUCOUS MEMBRANE PEMPHIGOID



## ■ INTRODUCTION

Mucous membrane pemphigoid (MMP) is an autoimmune, chronic inflammatory, subepithelial blistering disease. It predominantly affects middle-aged to elderly individuals, and occurs slightly more often in females. The annual incidence is approximately one in one million and there is no particular racial association. MMP is characterized by the formation of autoantibodies to the basement membrane zone (BMZ) antigens, particularly BP180 and BP 230. The BMZ autoantibodies activate complement that attracts neutrophils. The release of proteolytic enzymes from neutrophils causes detachment of the basal cells from the BMZ resulting in the subepithelial clefting at the lower lamina lucida and lamina densa levels.

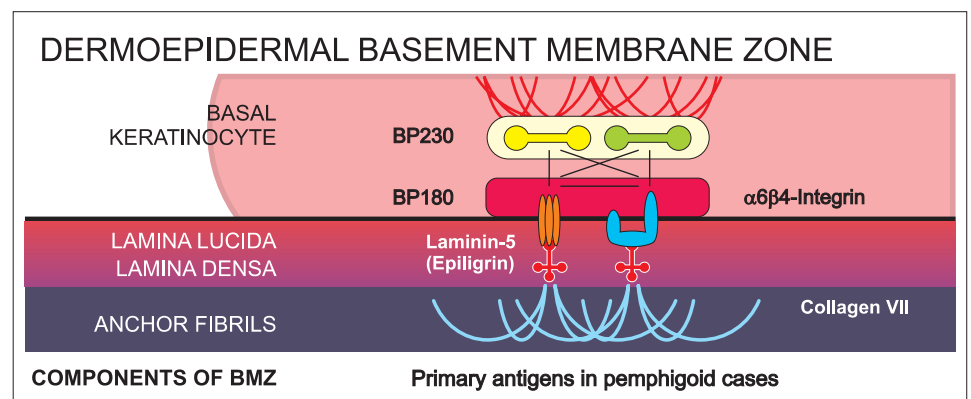
## ■ CLINICAL FEATURES

MMP can involve any mucosa with or without skin involvement. In decreasing frequency, affected tissues may include: the oral cavity, eye, nose, nasopharynx, anogenitals, skin, larynx, and esophagus. Skin involvement occurs in 20-30% of cases. Oral involvement mainly occurs as desquamative gingivitis. Common presentation is as gingival erythema and edema followed by desquamation of gingival mucosa or frank blister formation resulting in erosions. Erosions and ulcerations may also be observed on the buccal mucosa, palate, alveolar ridge, tongue, and the lip.

## ■ DIAGNOSIS

In addition to history and physical examination, the diagnosis of MMP is based on histopathology and immunofluorescence. The specimen for histopathological (H&E) examination should be a punch biopsy of an early, small, intact vesicle or an erythematous area. This type of specimen is most likely to reveal the primary pathology, including the location of the split (intraepithelial or subepithelial). This may also help differentiate this group of diseases from others that can present clinically with vesicles or bullae.

Direct immunofluorescence (IF) studies are very specific for the diagnosis of MMP. A biopsy for direct IF should be taken from normal-appearing tissue immediately adjacent to a clinical lesion (perilesional site). The immunoreactants (IgG, IgA and / or C3) in the tissue are seen as linear deposits in the BMZ. Serum antibody tests reveal the presence of serum antibodies with a similar reaction pattern as observed by direct IF on tissue samples. A whole blood, serum or blister fluid specimen is required to perform indirect IF testing.



## OPTIMAL SITES FOR BIOPSY FOR THE BEST DIAGNOSIS:

TISSUE	SITE	SPECIAL CONSIDERATIONS
Skin or Mucosa	Take the first biopsy from a perilesional area, adjacent to active or new blister	For Ocular MMP oral biopsies can be considered, when conjunctival biopsies of the perilesional site are difficult to obtain.
	Take a second biopsy from an adjacent normal area at least 3 mm from a lesion	

# MUCOUS MEMBRANE PEMPHIGOID

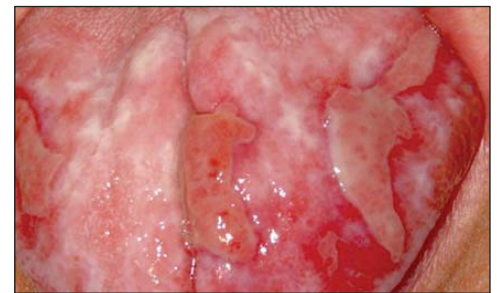## TREATMENT

The treatment of MMP poses a challenge because of its diverse clinical manifestations, and often requires a variety of specialists, including dermatologists, ophthalmologists, ear, nose, and throat specialists and dentists. A systematic review of efficacy of various medical treatments of MMP showed that almost no randomized, controlled, double-blind studies comparing the use of various therapeutic agents exist. Treatment decisions still rely heavily on the experience of individual clinicians. Systemic corticosteroids are the first line of treatment. However, because of their well known long-term adverse effects, corticosteroids must be combined with immunosuppressive and/or anti-inflammatory agents. For high-risk patients (i.e., patients with ocular, genital, laryngeal, esophageal or nasopharyngeal involvement) the First International Consensus on Mucous Membrane Pemphigoid recommends a combination of prednisone and cyclophosphamide, or alternatively azathioprine. Once clinical improvement is evident, the corticosteroids should be slowly tapered. Dapsone may be considered for high-risk patients, but patients who do not show any short-term improvement on this regimen should be

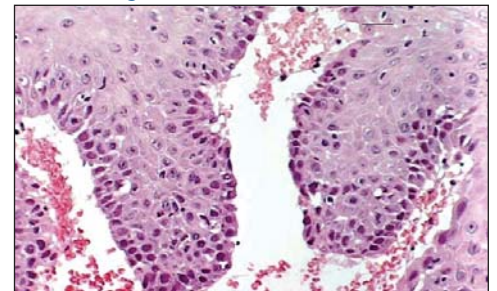
switched to cyclophosphamide. Intravenous immunoglobulins are another effective but expensive treatment option in high-risk patients. Low-risk patients may well be managed with topical therapy alone, such as corticosteroids or cyclosporine.

## SUGGESTED READING

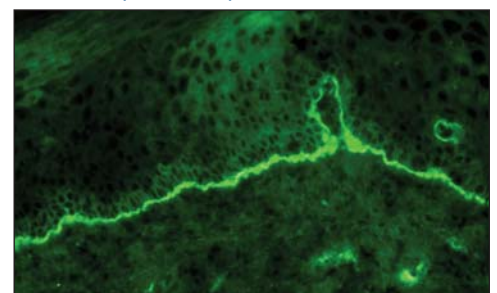
- Chan LS, Ahmed AR, Anhalt GJ, et al. The first international consensus on mucous membrane pemphigoid: definition, diagnostic criteria, pathogenic factors, medical treatment, and prognostic indicators. *Arch Dermatol* 138:370-9.
- Bagan J, Lo Muzio L, Scully C. Mucosal disease series. Number III. Mucous membrane pemphigoid. *Oral Dis*. 2005;11:197-218.
- Eschle-Meniconi ME, Ahmad SR, Foster CS. Mucous membrane pemphigoid: an update. *Curr Opin Ophthalmol*. 2005;16:303-7.
- Sacher C, Hunzelmann N. Cicatricial pemphigoid (mucous membrane pemphigoid): current and emerging therapeutic approaches. *Am J Clin Dermatol*. 2005; 6: 93-103.



CLINICAL PRESENTATION: Erythematous blisters on tongue



H&E: Sub-Epithelial Separation



IF: Linear Immunodeposits of IgG in the BMZ

## BIOPSY SPECIMEN SUBMISSION

Specimen collection kits are available free of charge. Please call (800) 537-8378 for an immediate shipment. Use appropriate tube for the biopsy as follows:

- H&E biopsy: Green tube
- Direct IF normal biopsy: Purple tube
- Direct IF lesional biopsy: Red tube

Specimens are collected by courier services, U.S. Postal Service and overnight carriers free of charge. Testing and reporting of the specimens are done within two business days. Reports are issued via mail, fax and through IMMCO Online, a HIPAA-compliant web tool at [www.immco.com](http://www.immco.com).



IMMCO Diagnostics, Inc. | 60 Pineview Drive  
Buffalo, NY 14228 USA | [www.immco.com](http://www.immco.com)  
toll free North America: 1-800-537-8378  
International: 1-716-691-0091 | fax: 1-716-691-0466