

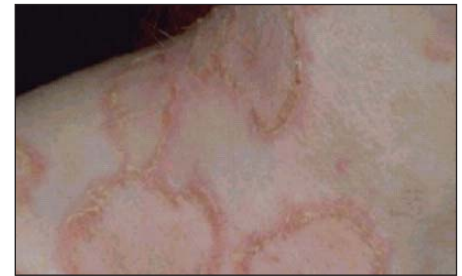## ■ INTRODUCTION

Pemphigus refers to a group of potentially life-threatening autoimmune blistering diseases of the skin and mucous membranes. Three primary subsets of pemphigus have been identified and include pemphigus vulgaris (PV), pemphigus foliaceus, and paraneoplastic pemphigus. Each type of pemphigus has distinct clinical and immunopathologic features. This condition accounts for approximately 70% of pemphigus cases. PV is uncommon, and the exact incidence and prevalence depends on the population studied. PV has been reported to occur worldwide. Incidence varies from 0.5-3.2 cases per 100,000. PV incidence is elevated in subjects of Ashkenazi Jewish descent as well as those of Mediterranean and Indian origin, however, this disease affects all races. Male-to-female ratio is approximately equal and the mean age of onset is approximately 50-60 years.

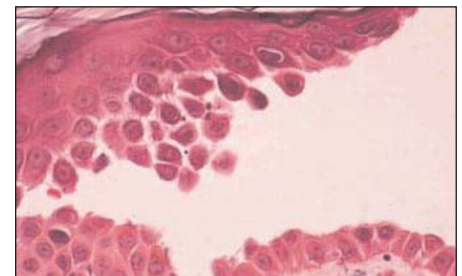
The pathophysiology of PV is characterized by circulating autoantibodies directed against intercellular antigens. Desmogleins are responsible for intercellular adhesion in the epithelium. The binding of autoantibodies results in a loss of cell-cell adhesion, a process termed acantholysis. Patients with active disease have circulating and tissue-bound autoantibodies to the intercellular antigens of the epithelium. Disease activity correlates with antibody titer in most patients.

## ■ CLINICAL FEATURES

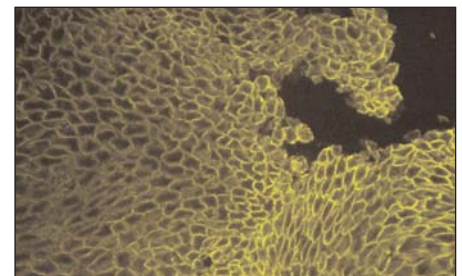
Mucous membranes typically are affected first in PV. Mucosal lesions may precede cutaneous lesions by months. Patients have ill-defined, irregularly shaped, gingival, buccal or palatine erosions, which are painful and slow to heal. The erosions extend peripherally with shedding of the epithelium. Other mucosal surfaces may be involved, including the conjunctiva, esophagus, labia, vagina, cervix, penis, urethra, and anus. The primary lesion of PV is a flaccid blister filled with clear fluid that arises on normal skin or mucosa. These blisters are fragile, so, intact blisters may be sparse. The contents soon become turbid or the blisters rupture producing painful erosions, which is the most common skin presentation. Erosions often are large because of their tendency to extend peripherally with the shedding of the epithelium. Nikolsky sign (firm sliding pressure with a finger separates normal-appearing epidermis producing an erosion) and Asboe-Hansen sign (Lateral pressure on the edge of a blister may spread the blister) may be positive.



CLINICAL PRESENTATION: Blisters on the skin



H&E: Acantholysis and supra-epithelial separation



IF: "spider-web" immunodeposits of IgG in the spaces between squamous epithelial cells

## OPTIMAL SITES FOR BIOPSY FOR THE BEST DIAGNOSIS:

Tissue	Site
Skin or Mucosa	Take the first biopsy from a perilesional area, adjacent to active or new blister
	Take the second biopsy from an adjacent or normal area at least 3 mm from a lesion

# PEMPHIGUS VULGARIS

## INCIDENCE OF INTERCELLULAR ANTIBODIES IN PEMPHIGUS

Substrate	No. Tested	No. Positive	% Positive
Monkey Esophagus	123	111	89
Guinea Pig Esophagus	123	103	81
Monkey or Guinea Pig Esophagus	123	122	99

## ■ DIAGNOSIS

To establish a diagnosis of PV, histopathology studies on a biopsy taken from the edge of a blister, direct immunofluorescence (IF) studies on normal-appearing (perilesional) skin or mucosa, and indirect IF serum studies are required.

Histopathology demonstrates an intradermal blister. The earliest changes consist of intercellular edema with loss of intercellular attachments in the basal layer. Suprabasal epidermal cells separate from the basal cells (a tombstone appearance) to form clefts and blisters. Direct IF demonstrates IgG intercellular deposition throughout the epidermis. This pattern of

staining on direct IF may also be seen in pemphigus vegetans, pemphigus foliaceus, and pemphigus erythematosus. Circulating intercellular antibodies are detected in 80-90% of patients with PV. The titer of circulating antibody correlates with disease course.

## ■ TREATMENT

Current treatment is largely based on systemic immunosuppression using corticosteroids, with azathioprine or other adjuvants. Newer therapies with potentially fewer adverse effects appear promising.

## ■ SUGGESTED READING

Black M, Mignogna MD, Scully C. Pemphigus vulgaris. *Oral Dis.* 2005; 11:119-30.

Bystryn JC, Rudolph JL. Pemphigus. *Lancet.* 2005; 366:61-73.

Tron F, Gilbert D, Mouquet H, Joly P, Drouot L, Makni S, Masmoudi H, Charron D, Zitouni M, Loiseau P, Ben Ayed M. Genetic factors in pemphigus. *J Autoimmun.* 2005; 24:319-28.

Hashimoto T. Recent advances in the study of the pathophysiology of pemphigus. *Arch Dermatol Res.* 2003; 295 Suppl 1:S2-11.



IMMCO Diagnostics, Inc. | 60 Pineview Drive  
Buffalo, NY 14228 USA | [www.immco.com](http://www.immco.com)  
toll free North America: 1-800-537-8378  
International: 1-716-691-0091 | fax: 1-716-691-0466

### BIOPSY SPECIMEN SUBMISSION

Specimen collection kits are available free of charge. Please call (800) 537-8378 for an immediate shipment. Use appropriate tube for the biopsy as follows:

H&E biopsy: Green tube  
Direct IF normal biopsy: Purple tube  
Direct IF lesional biopsy: Red tube

Specimens are collected by courier services, U.S. Postal Service and overnight carriers free of charge. Testing and reporting of the specimens are done within two business days. Reports are issued via mail, fax and through IMMCO Online, a HIPAA-compliant web tool at [www.immco.com](http://www.immco.com).